

# Histologic and Clinical Changes in Vulvovaginal Tissue After Treatment With a Transcutaneous Temperature-Controlled Radiofrequency Device

MONIQUE J. VANAMAN WILSON, MD,\* JOANNA BOLTON, MD,<sup>†</sup> ISABELA T. JONES, MD,<sup>‡</sup> DOUGLAS C. WU, MD, PhD,<sup>§</sup> ANTOANELLA CALAME, MD,<sup>||¶</sup> AND MITCHEL P. GOLDMAN, MD<sup>§¶</sup>

**BACKGROUND** Although transcutaneous temperature-controlled radiofrequency (TTCRF) may effectively treat vulvovaginal laxity (VVL), atrophic vaginitis (AV), orgasmic dysfunction (OD), and stress urinary incontinence (SUI), there is a lack of histopathologic evidence to validate its use.

**OBJECTIVE** Evaluate clinical and histological changes induced by vulvovaginal TTCRF.

**MATERIALS AND METHODS** This was a prospective, nonrandomized trial. Ten female subjects with mild-to-moderate VVL, with or without AV, OD, and/or SUI underwent 3 TTCRFs at 4-week intervals. Five subjects underwent pre- and post-treatment biopsies of the labia majora and vaginal canal for histology. Assessments were performed at baseline and Days 10, 30, 60, and 120.

**RESULTS** Investigator-rated VVL improved significantly from baseline to Day 10, with improvement maintained through Day 120 ( $p = .001$  and  $.001$ , respectively). Sexual satisfaction improved significantly by Day 60 ( $p = .001$ ). Improvement in AV reached significance at Day 120 ( $p = .048$ ). Although OD and SUI improved steadily, the difference in improvement did not reach statistical significance. Histology revealed that post-treatment increases in collagen, elastin, vascularity, and small nerve fibers.

**CONCLUSION** Transcutaneous temperature-controlled RF resulted in significant improvements in AV, VVL, and sexual satisfaction with milder improvements in OD and SUI. Post-treatment histology demonstrated neocollagenesis, neoeLASTogenesis, neoangiogenesis, and the first reported finding of TTCRF-related neurogenesis.

*Supported by ThermiGen LLC.*

Vulvovaginal rejuvenation is an increasingly popular procedure. Aging, menopause, weight fluctuations, and childbirth create mechanical forces on the vulva and vagina, and reduce the quality of connective tissue in the area, leading to symptoms of vulvovaginal laxity (VVL), atrophic vaginitis (AV), stress urinary incontinence (SUI), and orgasmic dysfunction (OD). Although women rarely discuss these issues, they can significantly detract from quality of life. In the past, options for addressing these concerns were limited to hormonal therapies,

lubricants, Kegel exercises, and traditional surgical intervention. Now, there are several laser and energy devices that can provide minimally and noninvasive vulvovaginal rejuvenation.<sup>1</sup>

Monopolar radiofrequency (RF) is an established modality for tissue tightening both on and off the face.<sup>2</sup> Radiofrequency induces collagen denaturation with subsequent contraction of fibrils, neocollagenesis, and activation of the healing cascade.<sup>3,4</sup> In 2010, Millheiser and colleagues<sup>5</sup> demonstrated the efficacy of monopolar

\*California Skin Institute, Sunnyvale, California; <sup>†</sup>Alliant Dermatology, The Villages, Florida; <sup>‡</sup>McLean Dermatology and Skincare Center, McLean, Virginia; <sup>§</sup>Goldman, Butterwick, Groff, Fabi and Wu, Cosmetic Laser Dermatology, San Diego, California; <sup>||</sup>Compass Dermatopathology, San Diego, California; <sup>¶</sup>Department of Dermatology, University of California, San Diego, San Diego, California

© 2018 by the American Society for Dermatologic Surgery, Inc. Published by Wolters Kluwer Health, Inc. All rights reserved.  
ISSN: 1076-0512 • Dermatol Surg 2018;0:1–9 • DOI: 10.1097/DSS.0000000000001453

RF in treatment of vaginal laxity after childbirth. This study found that RF safely improved laxity and sexual function up to 6 months post-treatment.

When compared with other RF technologies, the transcutaneous temperature-controlled RF (TTCRF) device offers several advantages in the treatment of skin laxity.<sup>2,6</sup> The TTCRF treatment probe contains thermistors and thermocouples that provide continuous temperature feedback to allow for fine control of the energy delivered to the treatment area, minimizing tissue injury and patient discomfort. Treatment with TTCRF is noninvasive and requires no downtime. There have been no reports of burns, blisters, or major complications as a result of treatment, which patients describe as very comfortable.

The TTCRF application for female genital rejuvenation (ThermiVa; Thermi, Irving, TX) has been shown to be a safe and effective office-based treatment for VVL.<sup>7</sup> Documented tightening effects for vulvar and vaginal laxity can approach prepregnancy and premenopausal levels. Tightening is visible immediately after the first treatment, with continued improvement noted over time. All patients in a study examining TTCRF for treatment of AV and dyspareunia reported an improvement in vaginal moisture at 2 weeks, with continued improvement over the following month.<sup>8</sup> Transcutaneous temperature-controlled RF was also shown to shorten time to orgasm by as much as 50%, improve clitoral sensitivity, and restore orgasmic ability in previously an orgasmic patient.<sup>9</sup> The precise mechanism for such improvements in sexual function is not known, but the author hypothesized that they may be due to the increased perfusion achieved through improving tissue quality.

Stress urinary incontinence may also be successfully treated using TTCRF. A recent study of 10 subjects with SUI who underwent TTCRF demonstrated that 70% of subjects had a negative cough test post-treatment with results sustained at 12 weeks. The clinical improvement in SUI was attributed to the improvement in AV seen on histological analysis of vaginal biopsies.<sup>10</sup>

Despite the impressive clinical and patient-reported results in the early studies of vulvovaginal TTCRF

treatment, there is a general lack of histopathologic evidence to validate the findings and to help explain the mechanism of improvement in AV, OD, and SUI. This study was developed to examine both the clinical and histological changes induced by vulvovaginal TTCRF treatment.

## Methods

### Study Design

This prospective, nonrandomized trial was performed at a single study site in accordance with the principles of the Declaration of Helsinki and was approved by an independent institutional review board.

### Subjects

The study population consisted of 10 adult female subjects with self-described mild-to-moderate primary or secondary VVL, with or without AV, OD, and/or SUI. Written informed consent and photographic release were obtained from every subject. Subjects were excluded from participation if they had a history of chronic systemic steroid or immunosuppressive medication use, an implanted medical device such as a pacemaker, a history of pelvic surgery or previous pelvic RF treatment within 5 years, an abnormal Pap smear within the previous 24 months, severe vulvovaginal dystrophy or dermatitis, uterine prolapse, severe urinary incontinence (greater than 10 episodes daily), and history of genital herpes with active lesions within the previous 6 months. Subjects were also excluded if they were pregnant or lactating, or had a copper intrauterine device in place.

### Study Procedures

A visual and speculum pelvic examination was conducted at screening to confirm that inclusion and exclusion criteria were met. All subjects then underwent 3 standard protocol TTCRF treatments to the vulvovaginal tissue using the ThermiVa device (Thermi) at 4-week intervals.<sup>7</sup> Radiofrequency energy was applied to the vaginal canal and the labia majora and minora through a specialized probe. The electrode tip was passed back and forth slowly and with wide

sweeps over each treatment area for 3 to 5 minutes, for a total treatment time of 30 minutes. The target temperature setting was 42 to 45°C, titrated to subject tolerance.

The first 5 subjects who volunteered for the histological evaluation underwent pre- and post-treatment biopsies. Two weeks before the initial treatment session, a punch biopsy of the right labia majora was performed using a 3-mm circular blade. A biopsy of the right vaginal canal, just proximal to the introitus, was also performed using Kevorkian biopsy forceps. Sixty days after the final treatment (Day 120), post-treatment biopsies were taken from the left vaginal canal and labia majora for comparison.

### **Histological Analysis**

After biopsy, samples were immediately transferred to 10% formalin in preparation for further histological processing. Pre- and post-treatment paraffin-embedded tissue samples from the labia majora and vaginal canal of 5 subjects were analyzed. The following stains were performed on every sample: Hematoxylin and Eosin (H&E), Colloidal Iron, Masson's Trichrome, Verhoeff-van Gieson, and immunohistochemical stains for CD34 and PGP9.5. Pre- and post-treatment tissues were stained on the same slide, to minimize staining variability.

### **Outcome Measures and Statistical Analyses**

At each visit, standardized 2D digital photography was performed. Subjects were evaluated at treatment Visit 1 (Day 0), 10 days after the first treatment (Day 10), treatment Visit 2 (Day 30), treatment Visit 3 (Day 60), and 2 months after the final treatment (Day 120). At each visit, investigators made clinical visual assessments of laxity using the 5-point Vulvovaginal Laxity Questionnaire (VVLQ), with scores ranging from none (0) to severe laxity (4).

At Days 0, 10, 30, 60, and 120, subjects completed self-assessments. Subject-rated VVL was scored using the Millheiser Vaginal Laxity Scale, which ranges from very loose (1) to very tight (7).<sup>5</sup> Subjects also completed the Millheiser Sexual Satisfaction Questionnaire (SSQ) in which they rated their satisfaction

derived from vaginal intercourse as none (1) to excellent (6), and the Female Sexual Function Index (FSFI), a detailed 19-question survey about sexual function and satisfaction.<sup>5,11</sup>

On Days 30, 60, and 120, subjects graded improvement in AV, SUI, and OD on a 4-point scale relative to baseline (0%–25% improved [1], 26% to 50% improved [2], 51% to 75% improved [3], and 76% to 100% improved [4]).

At the final visit on Day 120, each subject was asked to score their satisfaction with treatment from very unsatisfied (1) to very satisfied (5), and whether they would recommend the procedure to a friend or family member. Adverse events such as erythema, edema, ulcers, fistulas, burns, and blisters were assessed at each visit using a 5-point scale (none [0] to severe [4]).

All statistical analysis was performed with Microsoft Excel 2013 on an intent to treat basis. The Student's *t*-test was used to determine differences in means and interpreted at a 95% confidence interval. Descriptive statistics were provided for all continuous variables and frequencies for all categorical variables.

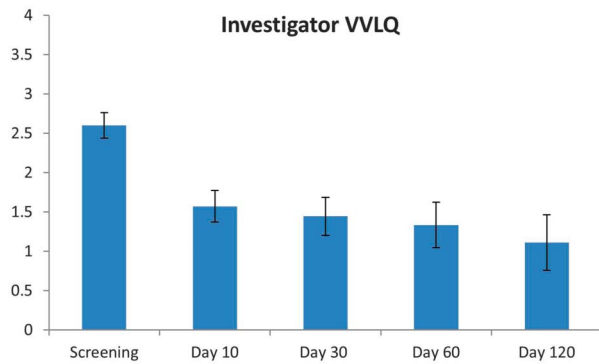
## **Results**

### **Subjects**

A total of 10 subjects were enrolled in this study. Of these, 5 subject volunteers underwent pre- and post-treatment biopsies. The mean age of all subjects was  $43.6 \pm 12.6$  years (range, 23–60 years). At baseline, 50% of subjects reported AV symptoms, 90% reported SUI, and 80% reported OD. One subject was discontinued from the study after treatment visit 2 (Day 30) because of noncompliance with study protocols.

### **Vulvovaginal Laxity**

By Day 10, investigator-rated VVL improved significantly from a mean of  $2.6 \pm 0.5$  at baseline to  $1.6 \pm 0.5$  ( $p = .001$ , Figure 1). This improvement was sustained at every subsequent time point, with a final mean VVL score at Day 120 of  $1.1 \pm 1.1$  ( $p = .001$ ). A representative result can be seen in Figure 2.



**Figure 1.** Investigator-rated VVLQ improved significantly from a mean of  $2.6 \pm 0.5$  at baseline to  $1.6 \pm 0.5$  by Day 10 ( $p = .001$ ). This improvement was sustained at every time point, with a final mean score at Day 120 of  $1.1 \pm 1.1$  ( $p = .001$ ). VVLQ, Vulvovaginal Laxity Questionnaire.

Subject-rated VVL improved significantly from a baseline mean of  $3.3 \pm 1.6$  to a mean of  $5 \pm 1.5$  at Day 120 ( $p = .03$ , Figure 3). However, in contrast to investigator-rated VVL scores, there was no significant improvement at the intervening follow-ups at Days 10, 30, or 60.

**Atrophic Vaginitis**

At Day 10, the mean improvement in AV symptoms relative to baseline was  $1.4 \pm 0.9$ . At Day 30, the mean improvement was unchanged at  $1.5 \pm 0.8$ . By Day 60, AV improvement rose to  $2.3 \pm 1.2$ . At the final visit on Day 120, subjects reported significantly more improvement in AV symptoms over those attained at Day 10, with a mean score of  $2.6 \pm 1.1$  ( $p = .048$ ) (Figure 4). At Day 120, 57.1% (4 of 7) of subjects

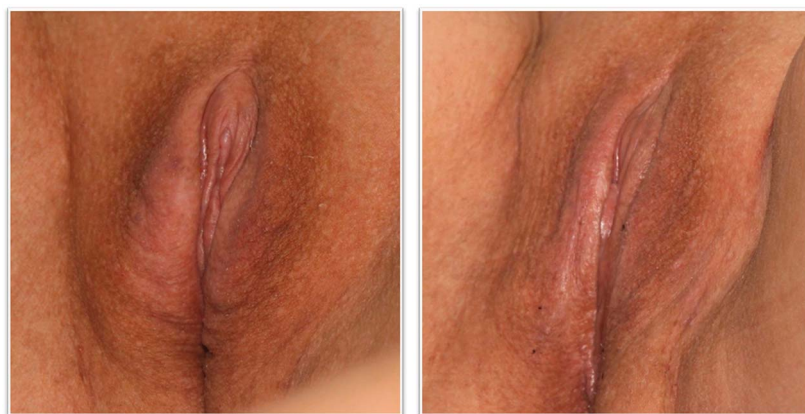reported 51% to 75% improvement and 14.3% (1 of 7) subjects reported 76% to 100% improvement in AV symptoms (Table 1). The remaining 28.6% (2 of 7) of subjects reported 0% to 25% improvement over baseline.

**Sexual Satisfaction**

Baseline mean subject sexual satisfaction was  $2.8 \pm 1.1$ . This improved slightly to  $3.3 \pm 1.1$  by Day 10 and  $3.7 \pm 1.3$  by Day 30 ( $p = .31$  and  $.12$ , respectively). At Day 60, improvement in sexual satisfaction was significant, with a mean of  $4.9 \pm 0.9$  ( $p = .001$ ). This improvement was maintained at Day 120 with a mean of  $4.3 \pm 1.5$  ( $p = .02$ , Figure 5).

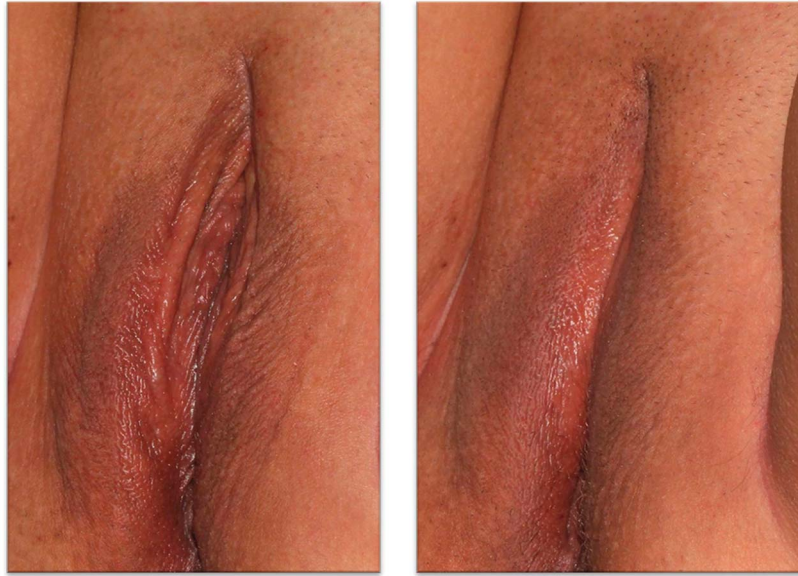Although subjects reported a steady improvement in OD over the course of the study, the difference in improvement at each follow-up did not reach statistical significance. On Day 10, the mean improvement score was  $1.4 \pm 0.7$ . By Day 30, the mean improvement score was  $1.6 \pm 0.9$  ( $p = .56$ ). On Day 60, the mean score reached  $2.1 \pm 0.9$  ( $p = .09$ ). At the final visit on Day 120, the mean score improved to  $2.4 \pm 1.5$  ( $p = .10$ ).

The FSFI provided more detailed information regarding the various aspects of the subjects’ sexual function. Subjects reported a significant increase in level of sexual interest from a baseline mean of  $1.9 \pm 0.7$  to a mean of  $2.8 \pm 0.8$  at Day 120 ( $p = .03$ ). Subjects also had a significant increase in their level of



**Figure 2.** A 36-year-old subject rated by investigators as (left) moderate laxity (3) at baseline and (right) trace laxity (1) at Day 120. Subject-rated VVL improved from “moderately loose” (2) to “very tight” (7) at Day 120. AV, atrophic vaginitis; VVL, vulvovaginal laxity.

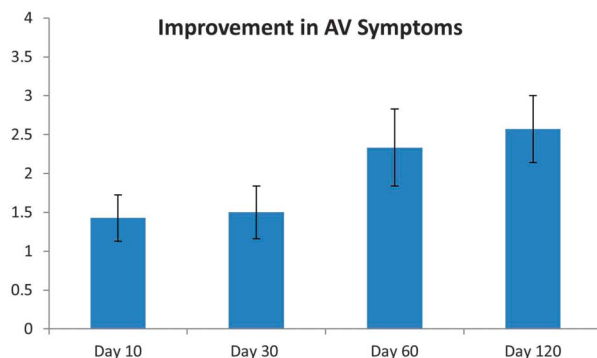




**Figure 3.** A 48-year-old subject rated by investigators as (left) moderate laxity (3) at baseline and (right) no laxity (0) at Day 120. Subject-rated VVL remained stable at “moderately loose” (2) from baseline to Day 120. VVL, vulvovaginal laxity.

sexual arousal during intercourse/sexual activity from a baseline mean of  $2.1 \pm 0.3$  to a mean of  $3.0 \pm 1.1$  at Day 30 ( $p = .045$ ). This heightened arousal was maintained through Days 60 and 120 ( $p = .01$  and  $.04$ , respectively). Perhaps, more importantly, subjects reported improved confidence in their ability to become aroused during sexual activity from baseline (mean  $1.9 \pm 0.6$ ) to Day 10 ( $2.5 \pm 1.2$ ,  $p = .04$ ). Confidence was maintained at each visit through Day 120 ( $3.0 \pm 1.0$ ,  $p = .01$ ).

Subjects' ability to maintain lubrication during sexual activity improved from a baseline mean of  $2.2 \pm 1.2$  to a mean of  $3.4 \pm 0.8$  at Day 60 ( $p = .04$ ). As expected,



**Figure 4.** Subject-reported improvement in AV symptoms relative to baseline increased throughout the study, and were significantly better at Day 120 than at Day 10, with a mean of  $2.6 \pm 1.1$  ( $p = .048$ ). AV, atrophic vaginitis.

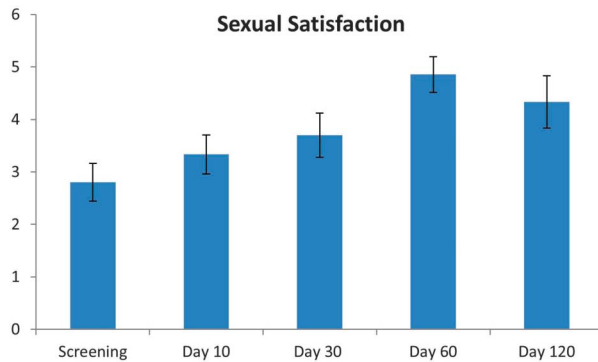
subjects additionally reported less difficulty maintaining lubrication, reaching significance at Day 10 ( $p = .03$ ) with results maintained through Day 120 ( $p = .01$ ).

Subject-reported improvement in ability to reach orgasm was significant only at Day 60 ( $p = .02$ ). Otherwise, ability to achieve orgasm was statistically unchanged from baseline, as it is reflected in OD scores. Despite the relative lack of change in orgasm function scores, subjects reported a significant improvement in satisfaction with their ability to achieve orgasm from baseline to Day 30 ( $p = .01$ ).

By the last visit at Day 120, subjects reported significant satisfaction with their overall sexual life from baseline to Day 120 ( $p = .03$ ).

**TABLE 1. Subject-Reported Improvement in Atrophic Vaginitis (AV), Orgasmic Dysfunction (OD), and Stress Urinary Incontinence (SUI) at Day 120**

Improvement Compared With Baseline	AV	OD	SUI
0–25%	28.6	42.9	22.2
26–50%	0	14.2	22.2
51–75%	57.1	0	22.2
76–100%	14.3	42.9	33.4



**Figure 5.** Sexual satisfaction was significantly improved over baseline at Day 60 ( $p = .001$ ). This improvement was maintained at Day 120 ( $p = .02$ ).

### Stress Urinary Incontinence

At Day 10, 37.5% of subjects (3 of 8) reported 51% to 75% improvement in symptoms of SUI. By Day 30, 44.4% of subjects (4 of 9) reported at least 50% improvement in SUI. On Day 60, 66.7% of subjects (6 of 9) reported at least 50% improvement in SUI, with 44.4% (4 of 9) describing the improvement as 76% to 100%. At the final visit on Day 120, 55.6% (5 of 9) had at least 50% improvement in SUI, with 33.3% of subjects (3 of 9) 76% to 100% improved, compared with baseline. Despite the gradual increase in the proportion of subjects experiencing notable improvement in SUI symptoms, there was no significant difference in improvement at Days 30, 60, or 120 compared with Day 10 ( $p = .86, .19, \text{ and } 0.30$ , respectively).

### Overall Satisfaction

At the final visit, 77.8% of subjects (7 of 9) stated that they were “satisfied” or “very satisfied.” Similarly, 77.8% of subjects (7 of 9) would recommend the procedure to friends and family.

### Histologic Changes

After 3 treatments with TTCRF, 80% of samples from the labia majora and 100% of those from the vaginal canal exhibited improved epidermal maturation with thickened mucosa, improved basal layer organization, and an increased granular cell layer (Table 2 and Figure 6).

Post-treatment, dermal, and submucosal collagen showed evidence of neocollagenesis, with more haphazardly arranged collagen bundles, increased number of fibroblasts, and increased stromal density (Figure 7).

Increased vascularity was evident in 2 labia majora and all vaginal canal biopsies (Figure 8). In 1 subject with abnormal ectatic vessels on pre-treatment biopsy, the ectatic blood vessels were decreased after treatment.

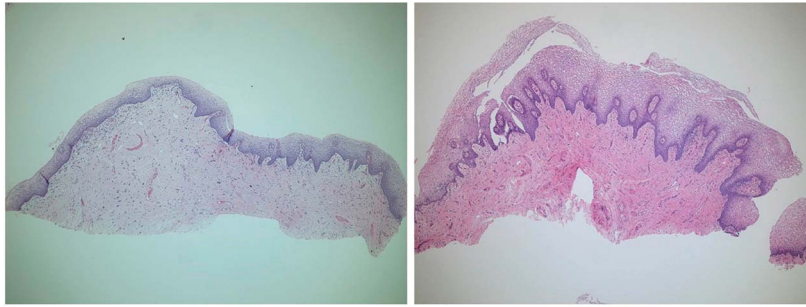
Neoelastogenesis, with increased density of elastic fibers, was evident in Verhoeff–van Gieson staining of labia majora and vaginal canal biopsies from 4

**TABLE 2. Post-Treatment Histologic Changes Among 5 Subjects**

Feature	Labia Majora	Vaginal Canal
<b>Epidermal changes</b>		
Maturation	Improved maturation ( $n = 4$ )	Improved mucosal maturation ( $n = 5$ )
Basal layer organization	Improved organization ( $n = 4$ )	Improved organization ( $n = 5$ )
Rete ridge architecture	Restored rete ridge architecture ( $n = 4$ )	Restored rete ridge architecture ( $n = 5$ )
<b>Stromal changes</b>		
Density/neocollagenesis	Increased collagen density ( $n = 5$ )	Increased collagen density ( $n = 5$ )
Vascularity	Increased vascularity ( $n = 2$ )	Increased vascularity ( $n = 4$ )
Fibroblasts	Increased fibroblasts ( $n = 3$ )	Increased fibroblasts ( $n = 3$ )
Mucin	Slightly decreased mucin ( $n = 2$ )	No change in mucin ( $n = 4$ )
Elastic fibers	Increased elastic fibers ( $n = 4$ )*	Increased elastic fibers ( $n = 4$ )*
Small nerve fiber density	Increased nerve fiber density ( $n = 3$ )	Increased nerve fiber density ( $n = 3$ )
Inflammation	Decreased inflammation ( $n = 2$ )†	No change ( $n = 5$ )

\*One subject had slightly decreased elastic fibers on post-treatment biopsy.

†One subject had evidence of incidental lichen sclerosis on pre-treatment vulvar biopsy and no evidence of lichen sclerosis on post-treatment biopsy.



**Figure 6.** Histology of the vaginal canal mucosa before (left) and at Day 120 after (right) treatment with TTCRF. Post-treatment, there was improvement in mucosal maturation with increased number of cell layers, increased papillary dermis, no flattening of the rete ridges, improved glycogenation, and denser stroma. Hematoxylin and eosin, 100X. TTCRF, transcutaneous temperature-controlled radiofrequency.

subjects. One subject exhibited a slight decrease in elastic fibers after treatment.

Samples from 3 subjects demonstrated a small, but distinct, increase in small nerve fibers within the papillary dermis after PGP9.5 staining of both labia majora and vaginal canal biopsies (Figure 9).

One subject demonstrated early incidental lichen sclerosus in the pre-treatment biopsy of the labia majora. This was not present on post-treatment histologic analysis. Similarly, another subject showed a marked decrease in dermal inflammation in the post-treatment biopsy of the labia majora.

Staining with colloidal iron revealed no significant changes in dermal or submucosal mucin deposition.

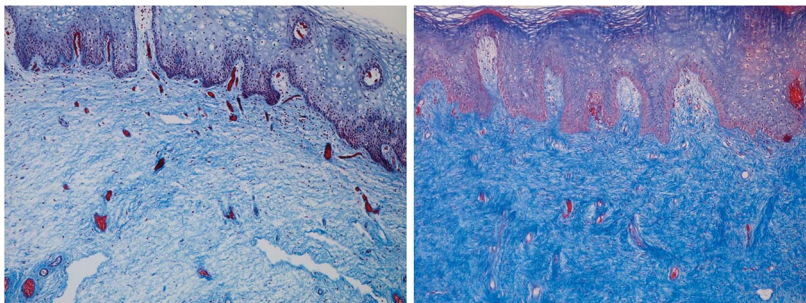
### **Safety**

No erythema, edema, ulcers, fistulas, burns, or blisters were observed at any of the follow-up time points.

Treatments were well tolerated, and there were no other unanticipated adverse side effects.

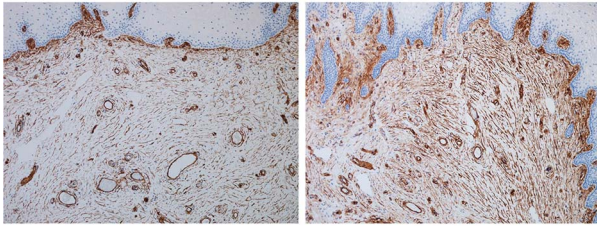
### **Discussion**

Previous pilot studies demonstrating that the efficacy of vulvovaginal TTCRF is further supported by the significant improvements in AV, sexual satisfaction, and investigator- and subject-rated VVL found in this study. There was also a steady, but statistically insignificant, improvement noted in SUI and OD. In fact, at the final visit on Day 120, 42.9% of subjects (3 of 7) reported at least 50% improvement in symptoms of OD. Interestingly, a few subjects who denied AV, SUI, and OD at baseline later reported improvement in symptoms of these conditions. This may be due to imperfect assessment tools used in this study, or because subjects had unrecognized, undiagnosed conditions at the start of the study that only became apparent once the symptoms improved. At the study conclusion, over 77% of subjects reported satisfaction with their results and were likely to recommend the procedure to others.



**Figure 7.** Histology of the vaginal mucosa before (left) and at Day 120 after (right) treatment with TTCRF. Post-treatment, there was a significant increase in newly formed, haphazardly arranged collagen. Masson's Trichrome, 100X. TTCRF, transcutaneous temperature-controlled radiofrequency.





**Figure 8.** Histology of the vaginal mucosa before (left) and at Day 120 after (right) treatment with TTCRF. Post-treatment biopsy demonstrated denser submucosal stroma and increased vascularity. CD34, 100X. TTCRF, transcutaneous temperature-controlled radiofrequency.

Although the benefits of TTCRF treatment are well described, the mechanisms behind some of these improvements remain unclear. As TTCRF gradually heats the target area to the therapeutically relevant temperature of 40 to 45°C, neocollagenesis and tissue tightening are induced. Improved blood supply to the treated tissues may stimulate vaginal glandular function and contribute to improved AV symptoms and sexual satisfaction. Improvements in orgasmic function and sexual satisfaction have sometimes been explained by the theory of thermal neurogenesis, which holds that repeated heat stimulation may induce the formation of new nerves. Previous *in vitro* work using a rat pheochromocytoma cell line demonstrated that repeated thermal stimulation at temperatures between 39.5 and 42°C resulted in the induction of neurite outgrowth.<sup>12</sup> However, conflicting data also exist which suggests that mild thermal injury (temperature exposure of between 36 and 40°C) in a chick animal model can inhibit new cell generation within the hypothalamus.<sup>13</sup> Clearly, these 2 studies used vastly different experimental models and therefore are not directly comparable. There have been no con-

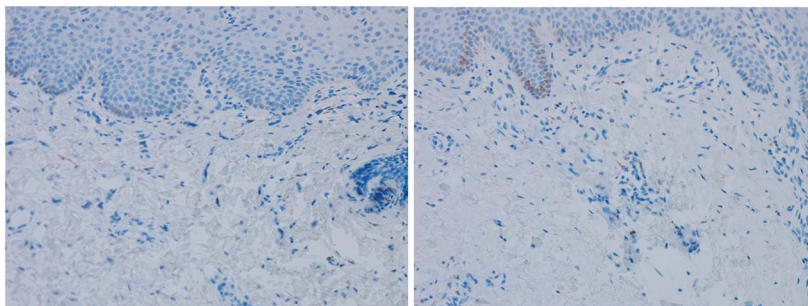
vincing clinical studies to date that have tested this hypothesis.

Based on the above theories and previous RF studies, the authors' group hypothesized that neocollagenesis, neoelastogenesis, and neoangiogenesis would be observed in post-TTCRF vulvovaginal biopsies. These hypotheses were confirmed with subtle but significant findings in post-treatment biopsies that exhibited the findings associated with rejuvenated skin and mucosa: improved epithelial maturation, restoration of vaginal transudate, increased collagen, new elastic fibers, and increased vascularity.

For assessment of small nerve fiber density, PGP9.5, the neuronal stain used in this study, is ideally performed on 50- $\mu$ m frozen sections. However, in this study, the decision to perform PGP9.5 staining was made after the tissue was already preserved in formalin, so the stain was performed on 5- $\mu$ m paraffin-embedded sections. Nonetheless, a subtle increase in nerve fibers was observed in 3 of 5 of these samples. To date, this is the first report of neurogenesis or neuroregeneration after treatment with vaginal TTCRF, although these findings should be confirmed using more standardized methods for small nerve fiber density assessment.<sup>14</sup>

As in previous studies of vaginal rejuvenation using TTCRF, no adverse events occurred in this study. Subjects found the procedure to be comfortable both during and after treatment.

Limitations of this study include its small sample size, the lack of a control group, and the absence of



**Figure 9.** Histology of the vaginal mucosa before (left) and at Day 120 after (right) treatment with TTCRF. Post-treatment, a small, but distinct, increase in small nerve fibers was evident within the papillary dermis. PGP9.5, 100X. TTCRF, transcutaneous temperature-controlled radiofrequency.



quantitative histological and/or molecular analysis. The effects of TTCRF treatment for female genital rejuvenation should be further explored by larger, randomized, sham procedure–controlled studies. A study specifically designed to examine treatment-induced neurogenesis may use PGP9.5, as well as other processing methods, to confirm or refute the findings presented here. Clinical experience with TTCRF suggests that although clinical effects gradually diminish after a series of treatments, outcomes often persist for 9 to 12 months.<sup>9</sup> Further investigation with biopsies at 6 and 12 months after treatment would elucidate the long-term histologic changes associated with treatment and perhaps offer a histologic correlate with the clinical observation that treatment-related improvements diminish with time.

## Conclusion

Vaginal rejuvenation with TTCRF resulted in significant improvements in AV, VVL, and sexual satisfaction without adverse events. Milder improvements in OD and SUI were observed. These clinical observations were supported by histologic findings of neocollagenesis, ne elastogenesis, neoangiogenesis, and the first report of possible TTCRF-related neurogenesis. Subject satisfaction with the results of treatment was high.

## References

1. Vanaman M, Bolton J, Placik O, Fabi SG. Emerging trends in nonsurgical female genital rejuvenation. *Dermatol Surg* 2016;42:1019–29.
2. Key DJ. Intergration of thermal imaging with subsurface radiofrequency thermistor heating for the purpose of skin tightening and contour improvement: a retrospective review of clinical efficacy. *J Drugs Dermatol* 2014;13:1485–9.
3. Zelickson BD, Kist D, Bernstein E, Brown DB, et al. Histological and ultrastructural evaluation of the effects of a radiofrequency-based nonablative dermal remodeling device: a pilot study. *Arch Dermatol* 2004;140:204–9.
4. Coad JE, Vos JA, Curtis A, Krychman M. Safety and mechanisms of action supporting nonablative radiofrequency thermal therapy for vaginal introitus laxity occurring in women after childbirth: histological study in the sheep vaginal model. *J Sex Med* 2013;10(Suppl 2):175.
5. Millheiser LS, Pauls RN, Herbst SJ, Chen BH. Radiofrequency treatment of vaginal laxity after vaginal delivery: nonsurgical vaginal tightening. *J Sex Med* 2010;7:3088–95.
6. Key DJ. Comprehensive thermoregulation for the purpose of skin tightening using a novel radiofrequency treatment device: a preliminary report. *J Drugs Dermatol* 2014;13:185–9.
7. Alinsod RM. Temperature controlled radiofrequency for vulvovaginal laxity. *Prime* 2015;3:16–21.
8. Alinsod RM. Transcutaneous temperature controlled radiofrequency for atrophic vaginitis and dyspareunia. *J Minim Invasive Gynecol* 2015;22:S226–7.
9. Alinsod RM. Transcutaneous temperature controlled radiofrequency for orgasmic dysfunction. *Lasers Surg Med* 2016;48:641–5.
10. Leibaschoff G, Izasa PG, Cardona JL, Miklos JR, et al. Transcutaneous temperature controlled radiofrequency (TTCRF) for the treatment of menopausal vaginal/genitourinary symptoms. *Surg Technol Int* 2016;XXIX:149–59.
11. Rosen R, Brown C, Heiman J, Leiblum S, et al. The female sexual function index (FSFI): a multidimensional self-report instrument for the assessment of female sexual function. *J Sex Marital Ther* 2000;26:191–208.
12. Kudo TA, Kanetaka H, Mochizuki K, Tominami K, et al. Induction of neurite outgrowth in PC12 cells treated with temperature-controlled repeated thermal stimulation. *PLoS One* 2015;10:e0124024.
13. Kisliouk T, Cramer T, Meiri N. Heat stress attenuates new cell generation in the hypothalamus: a role for miR-138. *Neuroscience* 2014;277:624–36.
14. Myers MI, Peltier AC. Uses of skin biopsy for sensory and autonomic nerve assessment. *Curr Neurol Neuro Sci Rep* 2013;13:323.

---

Address correspondence and reprint requests to: Monique J. Vanaman Wilson, MD, California Skin Institute, 603 S. Knickerbocker Dr. Sunnyvale, Sunnyvale, CA 94087, or e-mail: moniquewilsonmd@gmail.com